

# Physical, Esthetic and Functional Rehabilitation of a Unilateral Operated Cleft Lip and Palate Patient with Novel Method Part I

Abdulwahab Ismail Al-kholani<sup>1,2</sup>, Fatimah Mohammed AL-Rohmi<sup>1,2</sup>, Hassan Abdulwahab Al-Shamahy<sup>2,3\*</sup>,  
Mohamed Al-hemiari<sup>4</sup>

<sup>1</sup>Department of Conservative Dentistry, Faculty of Dentistry, Sana'a, University, Republic of Yemen

<sup>2</sup>Abdulwahab Al-kholani Dental Center, Sana'a, Yemen

<sup>3</sup>Department of Basic Sciences, Faculty of Dentistry, Sana'a University, Republic of Yemen

<sup>4</sup>Private Dental Laboratory, Sana'a, Yemen

Received Date: March 12, 2022; Published Date: April 15, 2022

**\*Corresponding author:** Hassan Abdulwahab Al-Shamahy (MD, PhD), Faculty of Medicine and Health Sciences, Sana'a University, Faculty of Medicine, Genius University for Sciences and Technology, Dhamar/Sana'a, Yemen, PO box: 775, Tel: +967-1-239551; Mobile: +967-770299847; E-mail: shmahe@yemen.net.ye

**Citation:** Hassan Abdulwahab Al-Shamahy, Abdulwahab Ismail Al-kholani, Fatimah Mohammed AL-Rohmi and Mohamed Al-hemiari. Physical, Esthetic and Functional Rehabilitation of a Unilateral Operated Cleft Lip and Palate Patient with Novel Method Part I. Clinic Case Repo. 2022;1(1):1002.

**Copyright © 2022 Hassan Abdulwahab Al-Shamahy.** This is an open access article published under the Creative Commons Attribution License, which permits unrestricted use, distribution, and reproduction in any medium, provided the original work is properly cited.

## Abstract

The purpose of this study is to overcome the problems of operated unilateral complete cleft lip and palate with protruding premaxilla in an adult patient older than 18 years of age. In the first 5 years of life, this patient underwent three surgical operations to close the soft tissues of the lip and palate. Unfortunately, clinical examination showed that protruded premaxilla, cleft lip, and palate still exist and

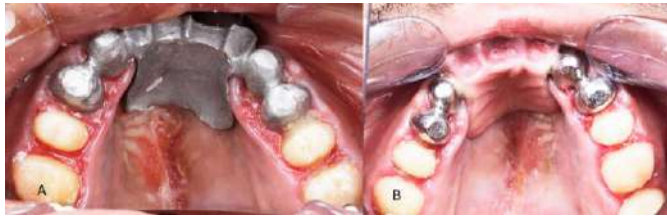asymmetry secondary to the different operations undergone in childhood. The patient is looking for an esthetic and functional solution for his case. As a result of previous failed operations, financial difficulties and distance traveled, this patient and his family are not willing to undergo new surgeries or orthodontics treatment and are looking for a less traumatic and costly solution. Accordingly, additional surgeries or orthodontic treatment were excluded. These factors challenged the treatment team and spur them to discover a novel method to solve the problems in this case

**Keywords:** Obturator prosthesis; Cleft palate; Cleft lip; Telescopic crowns; Unoperated adult cleft; Fixed prosthodontics

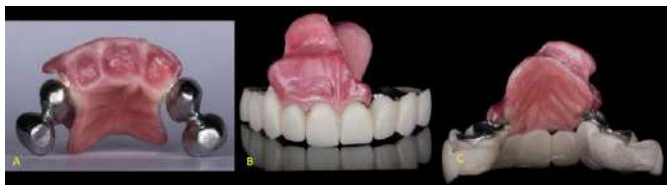## Introduction

With the lack of skills and medical services in underdeveloped communities and awareness among the patients, it is no surprise to find an adult with an unoperated or failed operated cleft lip and palate. Patients with either unilateral or bilateral cleft lip or palate present with several challenges to the multidisciplinary treatment team precisely when the patient was subjected to a previously failed operation [1]. Plastic surgery and tissue reconstruction are the treatment of choice [2]. An adequate-planned prosthetic treatment will result in satisfactory physical, esthetic, function, and psychology, providing alleviation of suffering for such patients [3-6]. Different designs of obturators available for patients with cleft

palate involve removable obturator supported by the alveolar ridge and retained with clasps around the teeth, magnetically retained obturator [7-9]. In the present case, we used fixed telescopic crowns which are part of the obturator coated with porcelain, and then a full-arch fixed prosthesis was placed over the telescopic crowns and obturator (Figure 1 and 2).



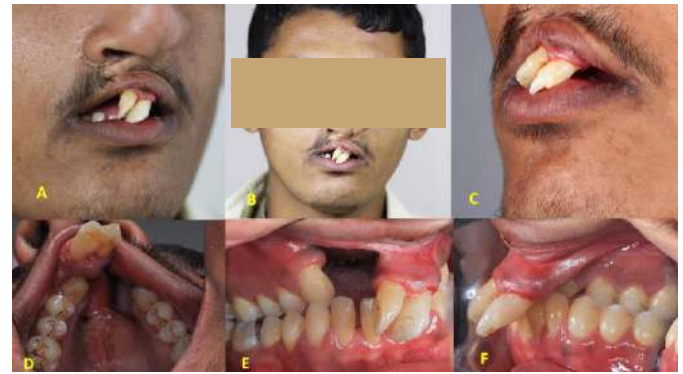**Figure 1:** Intraoral view for telescopic crowns on which the new obturator design (novel method) was attached before coating with porcelain.



**Figure 2:** Telescopic crowns on which the new obturator design (novel method) was attached after coating with porcelain A, Telescopic crowns on with obturator and temporary restoration frontal view B, and palatal view C.

**Case Report**

This 18-year-old patient attended our dental center with complaints of aesthetic, functional, and psychological impairment. Intraoral examination revealed evident a complete cleft involving the anterior alveolar bone, hard palate, and soft palate, dental malpositioning, and malocclusion, as well as a maxillary-mandibular discrepancy. Moderate gingivitis due to poor oral hygiene was also observed (Figure 3 A-F).

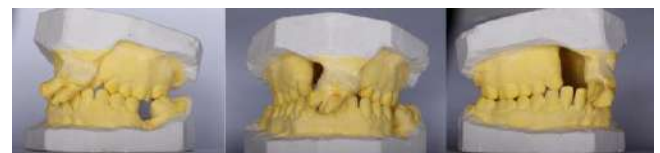

**Figure 3:** Upper row: extraoral views, right A, frontal B, and left C respectively. Lower row: intraoral view, palatal D, right E, and left F respectively.

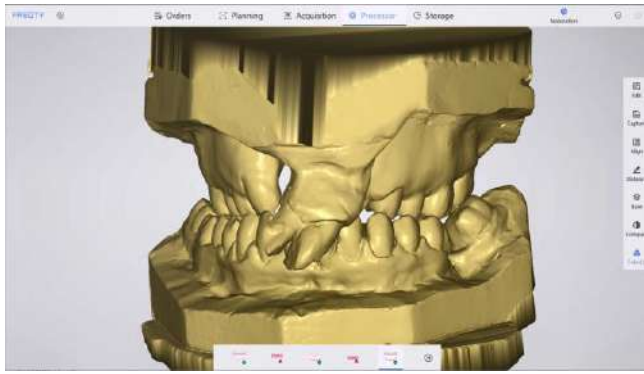
There were missing maxillary lateral incisors with rotated and proclined maxillary central incisors. A large scar on the lip also indicates surgical repair of the lip.

The treatment plan was explained to the patient and his accompanying brother. After the patient’s approval of the treatment plan that corresponds to his physical and social condition, written consent was requested and signed by his brother, including permission to photograph and publish his case for the purpose of scientific research and academic education.

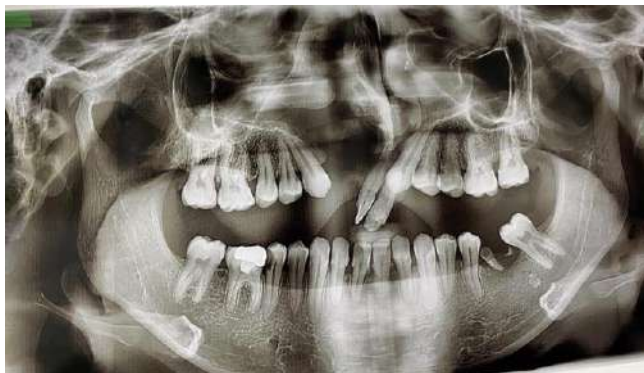The treatment procedure started by collecting data (Personal, Physical, Medical, and Dental History). A consent Letter was obtained prior to starting treatment procedures. Multidisciplinary Treatment Team (MTT) represents the cornerstone of the treatment plan which consists of different dental specialists. The clinical procedures were started by taking conventional and digital Impressions (Figure 4 and 5) followed by panoramic and CBCT radiographs (Figure 6 and 7).



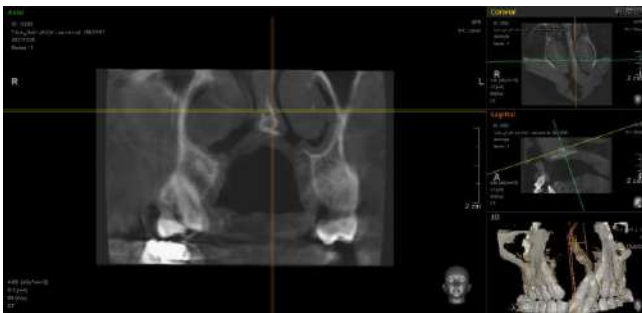**Figure 4:** Pre-operative conventional study models.



**Figure 5:** Digital study model.



**Figure 6:** Pre-operative Panoramic Radiograph.



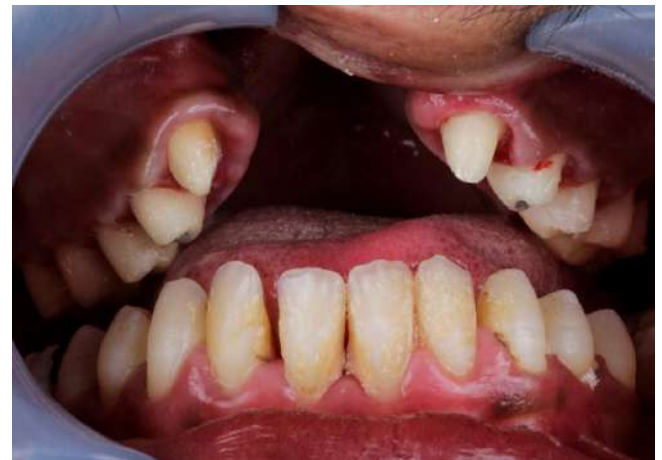**Figure 7:** Pre-operative Cone Beam Computed Tomography (CBCT).

After extensive review and reading in references and periodicals, we haven't found a new innovative way to treat such a condition, which forced us to think about creating a novel method by designing a new device to close the cleft palate for this patient.

A consultative meeting was held for the Multidisciplinary Treatment Team (MTT), during which an extensive discussion took place to find a new design to close the palatal defect. Lip and nose reconstruction was considered and repaired by the maxillofacial surgeon.

In this case report, we focused on treatment steps of the fixed prosthesis and telescopic crowns on which the new obturator design (novel method) was attached (Figure 1 and 2), and in the second part, we will focus on the steps of surgical and psychological treatment.

A decision was made to remove the maxillary central incisors with part of the underlying bone to facilitate the preparation and placement of a fixed prosthesis in the upper jaw (Figure 6). Periodontal, restorative, and root canal treatment were performed prior to the preparation of maxillary teeth, followed by oral hygiene instruction. After preparing the maxillary teeth, conventional and digital impressions of the upper and lower jaws were taken. The canines and the first premolar teeth were chosen to receive the telescopic crown on which the obturator was attached. Temporary restoration with acrylic obturator was placed and the patient asked to try it for 2 weeks. No Oroantral Communication (OAC) was observed while the patient is blowing, eating, or drinking.

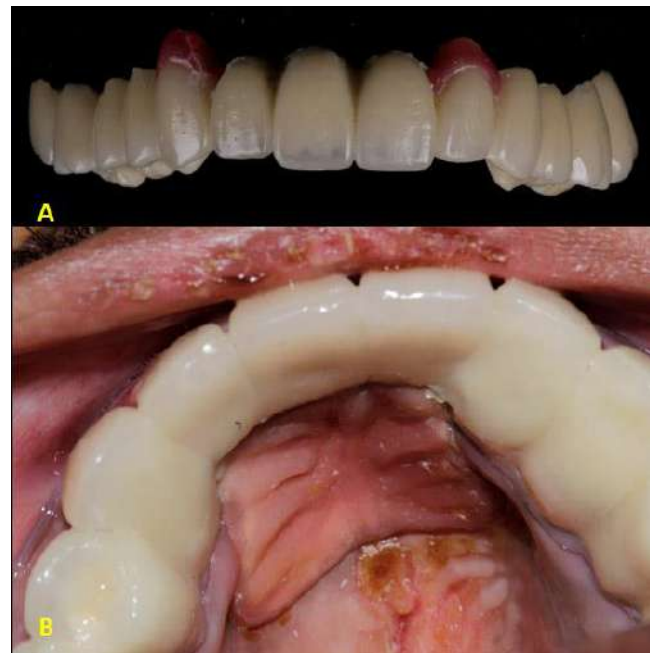


**Figure 8:** Showing the preparation of upper maxillary teeth after removal of maxillary central incisors.

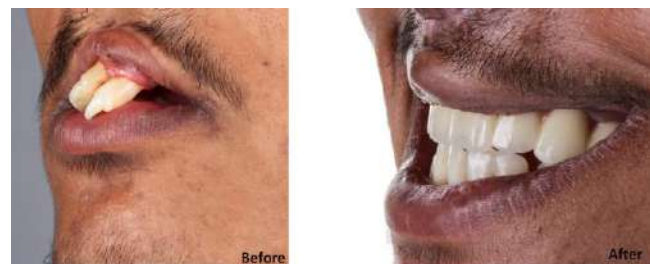When the new device (Telescopic crowns with obturator) was handed over to us, a metal try-in was performed in the patient's mouth before coating the device with porcelain (Figure 8). The device was returned to the laboratory to be coated with porcelain. After making sure that the device is completely fit long-term temporary cementation has been made to allow follow-up and evaluate the result after 6



months, then new impressions were taken to fabricate the final fixed bridge which will be installed over the telescopic crowns and obturator. In the last visit, during the trial of fixed prostheses in the patient's mouth, some necessary adjustments were made to adjust the occlusions and the aesthetic (Figure 9). In order to avoid a porcelain fracture when the final bridge meets the telescopic crowns and obturator, a layer of a special type of silicone was made, which was manufactured by the dental technician to absorb the occlusal forces, then long term temporary cementation was made. The patient was instructed to return to our dental center every month for a check-up. After 6 months patient came back without any complication and final cementation was carried out (Figure 10).



**Figure 9:** Final restoration for maxillary teeth (fixed prosthesis), extra oral view A and intraoral view showing the palatal surfaces of fixed bridge and the obturator B.



**Figure 10:** Final result before and after.

It is not easy to treat speech in patients with longstanding untreated clefts [4,5].

Although previous operations were performed to repair cleft palate and lips, these operations were not successful. In addition, the maxillary central incisors were not removed, which made the patient live 18 years without the lips meeting together. Accordingly, this patient suffers from difficulty in speech, and it has been linked to a lifelong impact on the quality of life of patients and the psychological effects resulting from inappropriate treatment at the right age and time.

**References**

1. Abu-Hussein M. Cleft lips and palate; the roles of specialists. *Minerva Pediatr.* 2011;63(3):227-32.
2. Yang CJ, Pan XG, Qian YF, and Wang GM. Impact of rapid maxillary expansion in unilateral cleft lip and palate patients after secondary alveolar bone grafting: review and case report. *Oral Surg Oral Med Oral Pathol Oral Radiol.* 2012;114:e25-30.
3. Daskalogiannakis J, Mercado A, Russell K, Hathaway R, Dugas G, Long RE Jr, et al. The Americleft study: an inter-center study of treatment outcomes for patients with unilateral cleft lip and palate part 3. Analysis of craniofacial form. *Cleft Palate Craniofac J.* 2011;48:252-8.
4. Kummer AW. Cleft palate and craniofacial anomalies: effect on speech and resonance. 2nd ed. New York: Thomson Delmar Learning; 2008;36-64.
5. Akinbami BO. Psychological effects of speech disorders in an adult patient with untreated cleft palate. *Niger J Med.* 2007;16: 381-3.
6. Goiato MC, Pesqueira AA, Ramos da Silva C, Gennari Filho H, Micheline Dos Santos D. Patient satisfaction with maxillofacial prosthesis. Literature review. *J Plast Reconstr Aesthet Surg* 2009;62:175-80. Epub 2008 Dec 6.
7. Ali Borzabadi-Farahani, John N Groper, Aaron M Tanner, Mark M Urata, Andre Panossian, Stephen L-K

Yen. "The nance obturator, a new fixed obturator for patients with cleft palate and fistula." *Journal of Prosthodontics: Implant, Esthetic and Reconstructive Dentistry*. 21.5. 2012;21(5):400-3.

8. Lopes JF, Pinto JH, de Almeida AL, Waldemarin Lopes MM, Dalben GS. Cleft palate obturation with branemark protocol implant-supported fixed denture and removable obturator. *Cleft Palate Craniofac J*. 2010;47:211-5.
9. Walter J. Obturators for acquired palatal defects. *Dent Update*. 2005;32(5):277-80,283-4.

Follow the URL for one-step submission

<https://clinicalscasereports.com/>